

Simultaneous Surface Ablation and CXL

The authors have 2 years' experience with SimLC for keratoconus.

BY ARTHUR CUMMINGS FRCS(Ed); AND EUGENE Y.J. NG, MRCOPHTH

Corneal collagen crosslinking (CXL) is a well-accepted and welcome addition to our arsenal of treatment options for keratoconus. Before CXL was approved in January 2007 for use in the European Union, treatment options to rehabilitate vision were quite limited—mostly to contact lenses of various descriptions and, when they failed, to penetrating keratoplasty (PK).

We now have just over 2 years' experience with CXL; follow-up has been promising indeed, with the progression of keratoconus slowing in 100% of eyes. CXL has stopped progression or improved the condition in all but seven eyes, three of which were cases of post-LASIK ectasia. The average amount of topographic improvement is approximately 2.00 D.

At the Wellington Eye Clinic, we have treated 28 eyes that already have a minimum of 6-month follow-up after CXL. In 23 eyes, CXL was the only treatment; the other five eyes were treated with the combined therapy of topography-guided PRK followed by CXL, which we have named *simultaneous laser correction with CXL* (SimLC).

In many cases, PRK is used to fix residual refractive errors or corneal asymmetry after CXL.^{1,2} The technique removes tissue (depending on the ablation depth) from the previously crosslinked cornea. The cornea crosslinks to a depth of approximately 200 to 350 μm , and the strongest crosslinking effect is in the anterior 100 μm of the stroma.³⁻¹²

Depending on the ablation depth of the intended laser treatment, a potentially significant amount of the strongest crosslinked fibers may be ablated. Furthermore, the superior peripheral (ie, hyperopic) ablation profile of the topography-guided treatment may redistribute corneal stress away from the inferior cornea when combined with CXL.

Theo Seiler, MD, PhD, of Zurich, Switzerland, is the pioneer of CXL. His technique suggests that 400 μm of corneal stroma are required to protect the endothelium and intraocular structures. Because the laser treatment is performed first with our SimLC technique, enough corneal stroma remains intact before CXL is performed.

We use the Allegretto excimer laser (WaveLight AG, Erlangen, Germany) for the topography-guided ablation to improve the corneal asymmetry. The synergistic improvement of shape, based on the CXL effect, allows us to reduce

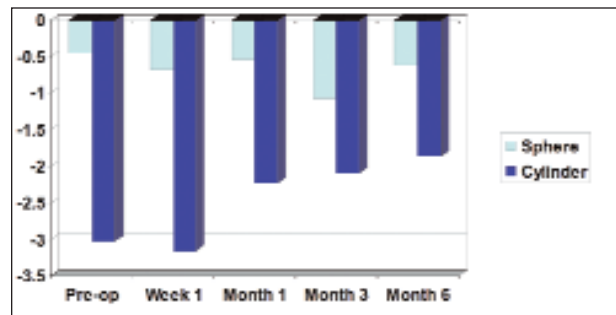


Figure 1. Refractive error over the first 6 months following CXL.

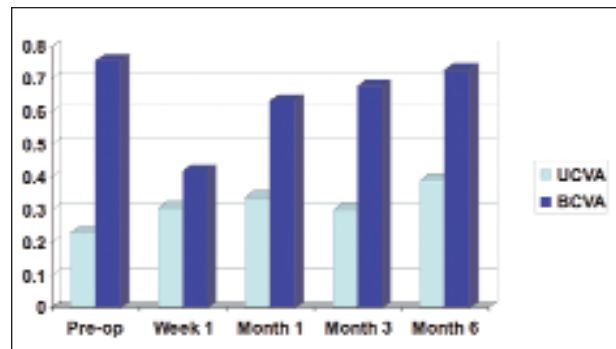


Figure 2. UCVA and BCVA over the first 6 months following CXL.

the laser treatment by approximately 50%. The ablation is performed in such a way as to leave 400 μm of stroma before CXL commences.

SimLC has produced remarkable improvements in corneal topography. In addition to our 28 cases with 6-month follow-up, we have also performed SimLC in five more cases; however, in these cases the only ablation is that of the topography-guided element, with refractions entered as zero. Early results suggest that such cases will have a more normalized corneal shape, especially if there is significant preexisting myopia, compared with cases that use a limited refraction.

In our original cohort of 28 patients with keratoconus undergoing CXL, the average steepest area on the cornea was 55.25 D preoperatively; postoperatively, it was 53.87 D, and the average amount of flattening over the cone was 1.38 D. The total amount of improvement in corneal remodeling (ie, the combined effect of flattening of the infe-

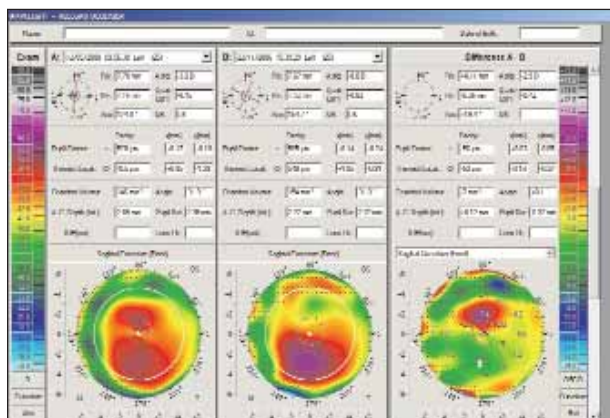


Figure 3. Topography plots of a left eye that underwent SimLC. This was the author's first case of SimLC. The middle map is the preop topography; the map on the left is the postop topography 18 months later. The map on the right is the difference map between the two.

rior steep portion and the steepening of the superior flat portion) was 2.65 D. Table 1 shows our findings comparing the results in CXL and SimLC patients.

Endothelial cell counts were normal following SimLC; there were no significant differences between groups. The demarcation line, observed in most cases on anterior segment optical coherence topography, corresponded with the slit-lamp estimation of CXL's depth of effect. This did not correlate to preoperative corneal thickness.

One keratoconic patient had CXL performed on her left eye and SimLC on her right. At 6 months, the left eye showed some regression, and 0.60 D of flattening was noted over the steepest area and 0.80 D of steepening over the flattest area. The overall improvement in corneal shape was 1.40 D. In the right eye, there was a marked regression of keratoconus, with 3.00 D of flattening over the steepest area and 0.80 D of steepening over the flattest area. Therefore, she experienced an overall 3.80 D improvement in corneal shape.

Her UCVA at the initial visit was 6/60-1 and 6/38+1 in the right and left eyes, respectively. At her 1 year visit, UCVA was 6/12 and 6/20, respectively. BCVA remained the same (6/7.5 and 6/6-2 in right and left eyes, respectively). Her refractive error improved in both eyes; cylinder was reduced by 1.50 D in the right eye and by 3.50 D in the left.

It is important to remember that the primary indication

TABLE 1. COMPARISON OF CXL AND SimLC

	CXL (n=23)	SimLC (n=5)
Steepest preop area	56.70 D	47.40 D
Steepest postop area	55.30 D	45.20 D
Average flattening	1.40 D	2.20 D
Overall effect	2.35 D	6.10 D

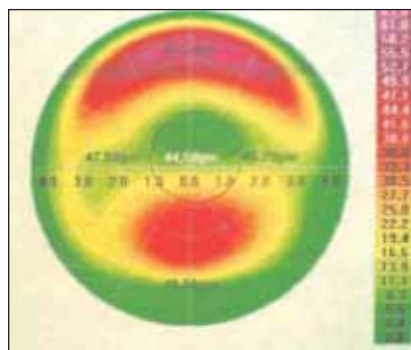


Figure 4. The ablation profile of the PRK to achieve the SimLC result in Figure 3.

for CXL is to slow or halt the progression of keratoconus. Regression of the corneal shape, as we have seen in this specific patient, is considered a bonus. Of our 23 cases of CXL, only eight had no

improvement in corneal shape. In fact, seven showed progression of keratoconus, with the cone on average 1.25 D steeper postoperatively; three had post-LASIK keratectasia. Every case of SimLC improved dramatically, the smallest improvement being 4.00 D and the biggest being 8.00 D (measured by delta keratometry readings).

The general changes produced during SimLC are flattening of the cone and improvement of the overall shape. This occurs because SimLC flattens the steepest area (ie, inferior) and steepens the flattest area (ie, superior). After the procedure, patients are easier to fit with contact lenses, which are also better tolerated than before. Increased functionality and delayed or eliminated need for PK are also benefits of using SimLC. Patients are satisfied with the knowledge that something has been done specifically to slow down the progression of the disease.

CXL has been a successful and useful addition to the treatment options for keratoconus. Indications for treatment will still change, and probably widen, as further studies shed more light on the subject. SimLC has raised the bar even further with a treatment that appears safe and effective. ■

Author's Note: Endothelial cell counting and anterior segment OCT acquisitions were provided by Laser Eye Clinic, Mater Private Hospital, Dublin.

Arthur Cummings, FRCS(Ed), is a consultant ophthalmologist at the Wellington Eye Clinic, Dublin, Ireland. Dr. Cummings is a member of the CRST Europe Editorial Board. He states that he has no financial interest in the products or companies mentioned. He may be reached at e-mail: abc@wellingtoneyeclinic.com.

Eugene Y.J. Ng, MRCOphth, is a Specialist Registrar at Cork University Hospital. Dr. Ng states that he has no financial inter-

TAKE-HOME MESSAGE

- SimLC with CXL produces topographic improvements.
- The primary indication is to slow or halt progressive keratoconus; regression of the corneal shape is a bonus.

Medicare HTM

Quality Vision



MediaSun



Single Piece
Hydrophobic Acrylic IOL

Extreme double-square
edge around entire
optic periphery
UV & blue blocking

To understand visual
complaints
To identify the origin
of aberrations

with confident analysis
by «Ray Tracing»



iTrace™

www.medicare-htm.com

SFO Booth P01

33 2 51 78 90 90

Medicare-HTM 3 rue Alain Bombard 14821 Saint-Herblain cedex
Fax : 33 (0)2 40 59 00 15 - email: contact@medicare-htm.com

COVER STORY

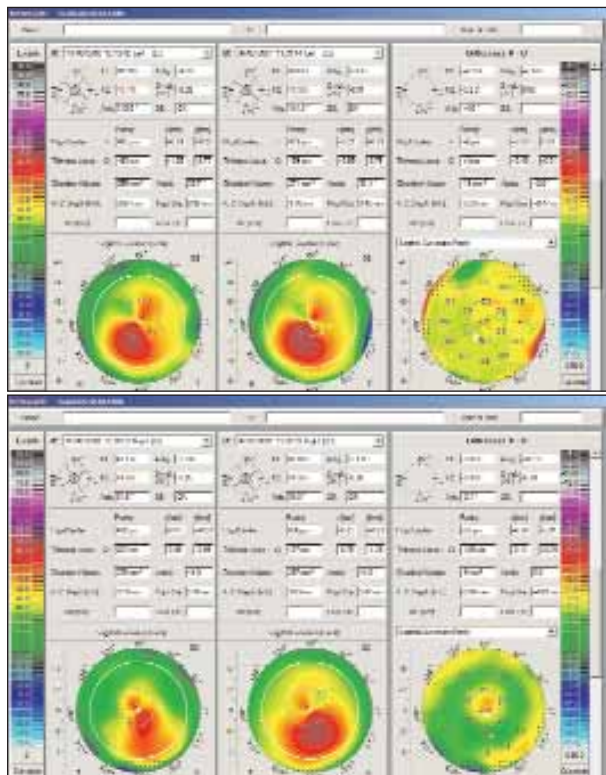


Figure 5. (Above) CXL and (below) SimLC in different eyes of the same patient.

est in the products or companies mentioned. He may be reached at e-mail: surgery.eyeg@gmail.com.

1. Kanellopoulos AJ, Binder PS. Collagen cross-linking (CCL) with sequential topography-guided PRK: A temporizing alternative for keratoconus to penetrating keratoplasty. *Cornea*. 2007;26:891-895.
2. Kanellopoulos AJ. Limited topography-guided surface ablation followed by stabilization with collagen cross-linking with UV irradiation and riboflavin for keratoconus. Paper presented at the: American Academy of Ophthalmology 2007 Annual Meeting; November 10-13, 2007; New Orleans.
3. Spoerl E, Huhle M, Seiler T. Induction of cross-links in corneal tissue. *Experimental Eye Research*. 1998;66(1):97-103.
4. Wollensak G, Spoerl E, Seiler T. Riboflavin/ultraviolet-a induced collagen crosslinking for the treatment of keratoconus. *Am J Ophthalmology*. 2003;135(5):620-627.
5. Kenney MC, Chwa M, Atilano R, Tran A, Carballo M, Saghizadeh M, Vasiliou V, Adachi W, and Brown DJ. Increased levels of catalase and cathepsin V/L2 but decreased TIMP-1 in keratoconus corneas: evidence that oxidative stress plays a role in this disorder. *Invest Ophthalmol Vis Sci*. 2005;46:823-832.
6. Chwa M, Atilano SR, Reddy V, Jordan N, Kim DW, and Kenny MC. Increased stress-induced generation of reactive oxygen species and apoptosis in human keratoconus fibroblasts. *Invest Ophthalmol Vis Sci*. 2006;47:1902-1910.
7. Pinelli R. C3-R Treatment opens new frontiers for keratoconus and corneal ectasia. *Eyeworld*. 2007;5:34-36.
8. Pinelli R. C3-R (UVA + riboflavin) for the treatment of keratoconus and corneal ectasia: results at six months in 20 eyes. Paper presented at the: 2006 Joint Meeting of the American Academy of Ophthalmology and Asia Pacific Academy of Ophthalmology; November 11-14, 2006; Las Vegas.
9. Mazzotta C, Balestrazzi A, Traversi C, Baiocchi S, Caporossi T, Tommasi C, Caporossi A. Treatment of progressive keratoconus by riboflavin-UVA-induced cross-linking of corneal collagen: ultrastructural analysis by Heidelberg Retinal Tomograph II in vivo confocal microscopy in humans. *Cornea*. 2007;26(4):390-397.
10. Wollensak G, Spoerl E, Seiler T. Stress-strain measurements of human and porcine corneas after riboflavin-ultraviolet-A-induced cross-linking. *J Cataract Refract Surg*. 2003;29(9):1780-1785.
11. Wollensak G, Wilsch M, Spoerl E, Seiler T. Collagen fiber diameter in the rabbit cornea after collagen crosslinking by riboflavin/UVA. *Cornea*. 2004;23(5):503-507.
12. Spoerl E, Mrochen M, Sliney D, Trokel S, Seiler T. Safety of UVA-riboflavin cross-linking of the cornea. *Cornea*. 2007;26(4):385-389.